

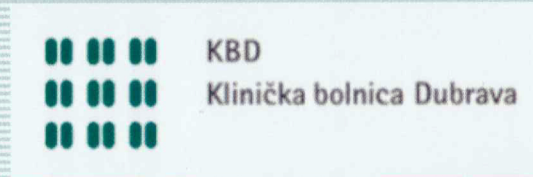
Osteochondritis dissecans of the knee in an individual from ninth century Croatia – Morphological and Radiological analysis

Tatjana Cicvara-Pećina ¹, Anita Adamić ², Marko Pećina ³,
Mario Šlaus ²

¹ Department of Radiology University Hospital Dubrava, Zagreb, Croatia

² Anthropological Center, Croatian Academy of Sciences and Arts, Zagreb, Croatia

³ University of Zagreb, School of Medicine, Zagreb, Croatia



Osteochondritis dissecans of the knee in an individual from ninth century Croatia – Morphological and Radiological analysis

Tatjana Cicvara-Pećina 1, Anita Adamić 2, Marko Pećina 3, Mario Šlaus 2

1 Department of Radiology University Hospital Dubrava, Zagreb, Croatia

2 Anthropological Center, Croatian Academy of Sciences and Arts, Zagreb, Croatia

3 University of Zagreb, School of Medicine, Zagreb, Croatia

We present and describe an example of osteochondritis dissecans identified in the Osteological Collection of the Croatian Academy of Sciences and Arts. The case of osteochondritis dissecans described in this report was recovered from a cemetery in the Dalmatian hinterland, north-east of Split. The individual exhibiting osteochondritis dissecans was recovered from grave number 16 that belongs to the younger phase of the cemetery which lasted during the second half of the 9th century A.D. Osteochondritis dissecans was noted in the distal femur of a subadult individual. The pathological changes consistent with osteochondritis dissecans are present on both medial femoral condyles. The lesion on the right femoral condyle is an oval crater-like defect with well defined margins and a porous floor of rough trabecular bone. The lesion on the left femoral condyle is basically, with two small provisions, identical to the one on the right side. The first is that it is slightly smaller, while the second is that unlike its antimere, it has a well preserved bone fragment that perfectly fits into the osteochondritic pit. A radiographic analysis of the femoral condyles supports a diagnosis of osteochondritis dissecans and shows a well-demarcated radiolucent defect in the articular surfaces of both joints surrounded by a thin sclerotic repair zone. According to classification systems this degree of change corresponds to stage 3 or grade 3 osteochondritis dissecans – a detached but non-displaced fragment. As is evident from this example it is clear that during the last 1100 years there have been no significant morphological or radiological changes in the characteristics of osteochondritis dissecans.